



Owner's Copy

**PennHIP Report**

Referring Veterinarian: Dr Mark Bramwell Email: forms@southforkanimalclinic.com	Clinic Name: South Fork Animal Clinic Clinic Address: 3852 E 300 N Rigby, ID 83442 Phone: (208) 745-7791 Fax: (208) 745-0034
--	--

**Patient Information**

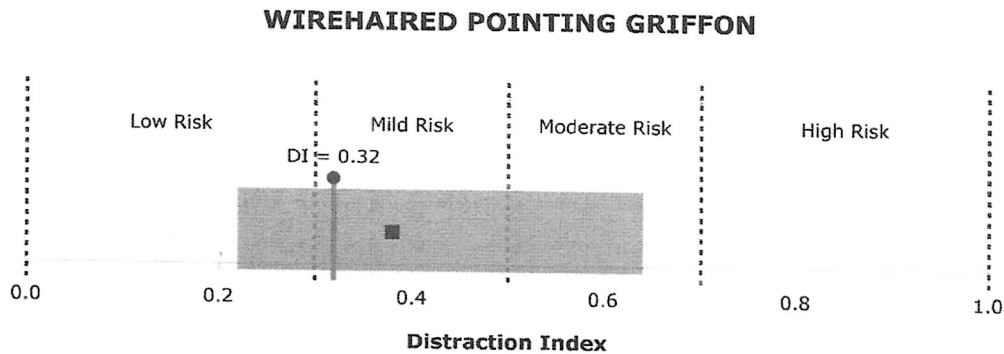
Client: Stewart, David Patient Name: Coop Reg. Name: Hun Hill Magnum PennHIP Num: 164604 Species: Canine Date of Birth: 27 Jul 2020 Sex: Male Date of Study: 08 Nov 2021 Date of Report: 11 Nov 2021	Tattoo Num: None Patient ID: 73392 Registration Num: SS20664008 Microchip Num: 985141004300846 Breed: WIREHAIRD POINTING GRIFFON Age: 16 months Weight: 55 lbs/24.9 kgs Date Submitted: 08 Nov 2021
--	--

**Findings**

Distraction Index (DI): Right DI = 0.32, Left DI = 0.21.  
Osteoarthritis (OA): **No radiographic evidence of OA for either hip.**  
Cavitation/Other Findings: No cavitation present.

**Interpretation**

Distraction Index (DI): The laxity ranking is based on the hip with the greater laxity (larger DI). In this case the DI used is 0.32.  
OA Risk Category: The DI is between 0.31 and 0.49. This patient is at mild risk for hip OA.  
Distraction Index Chart:



**BREED STATISTICS:** This interpretation is based on a cross-section of 1116 canine patients of the WIREHAIRD POINTING GRIFFON breed in the AIS PennHIP database. The gray strip represents the central 90% range of DIs (0.22 - 0.64) for the breed. The breed average DI is 0.38 (solid square). The patient DI is the solid circle (0.32).

**SUMMARY:** The degree of laxity (DI = 0.32) falls within the central 90% range of DIs for the breed. This amount of hip laxity places the hip at a mild risk to develop hip OA. **No radiographic evidence of OA for either hip.**