AIS PennHIP

(877) 727-6800 www.antechimagingservices.com

*For best printing results please use Chrome or IE.
Owner's Copy

PennHIP Report

Referring Veterinarian: Dr Mark Bramwell	Clinic Name: Bramwell Animal Hospital
Email: info.bramwellah@gmail.com	Clinic Address: 3804 E 37 N Unit 4
	Rigby, ID 83442
	Phone:
	Fax:

Patient Information

Client: Stewart, David	Tattoo Num:
Patient Name: Roxy MC#956000018251685	Patient ID: 2253
Reg. Name: Mountain River Roxy	Registration Num: 5552566903
PennHIP Num: 236957	Microchip Num: 956000018251685
Species: Canine	Breed: WIREHAIRED POINTING GRIFFON
Date of Birth: 06 Apr 2025	Age: 17 months
Sex: Female	Weight: 52.2
Date of Study: 03 Sep 2026	Date Submitted: 04 Sep 2026
Date of Report: 11 Sep 2026	

Findings

Distraction Index (DI): Right DI = 0.27, Left DI = 0.23.

Osteoarthritis (OA): **No radiographic evidence of OA for either hip.**

Cavitation/Other Findings: No cavitation present.

Interpretation

Distraction Index (DI): The laxity ranking is based on the hip with the greater laxity (larger DI). In this case the DI used is 0.27.

OA Risk Category: The DI is less than or equal to 0.30. This patient is at minimal risk for hip OA.

Distraction Index Chart:

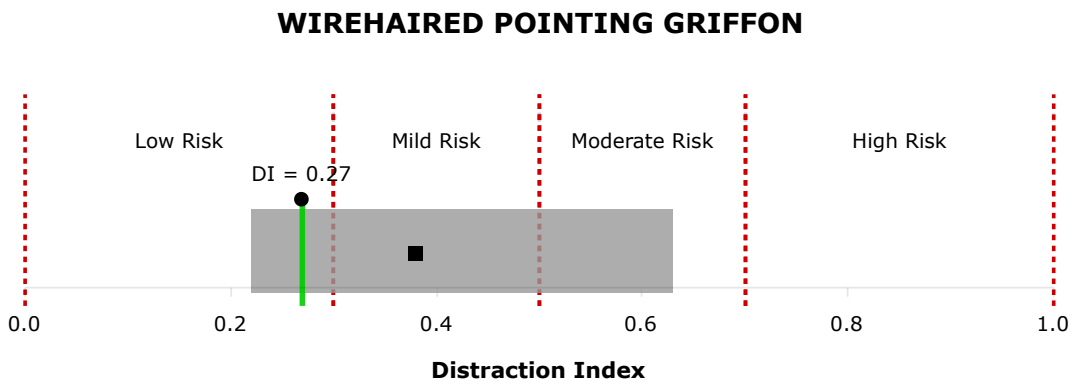

BREED STATISTICS: This interpretation is based on a cross-section of 1339 canine patients of the WIREHAIRED POINTING GRIFFON breed in the AIS PennHIP database. The gray strip represents the central 90% range of DIs (0.22 - 0.63) for the breed. The breed average DI is 0.38 (solid square). The patient DI is the solid circle (0.27).

SUMMARY: The degree of laxity (DI = 0.27) falls within the central 90% range of DIs for the breed. This amount of hip laxity places hip at a minimal risk to develop hip OA. **No radiographic evidence of OA for either hip.**